Aesthetic Medicine 2023; Vol. 9, N. 4: e2023020 DOI: 10.57662/am.v9i4.14944 © Mattioli 1885

Original article

Assessment of neck lines: development and validation of IBSA photographic scale

Antonello Tateo[1], Elena Goltsova[2], Eyal Kramer[3], Michela Zazzaron[4], Natalia Ribè[5], Riccardo Forte[6], Arturo Lanzarotti[7], Noémie Lecoeur[8], Franco Grimolizzi[9], Nicolas Dapis[8], Gilberto Bellia[9]

[1]Private Practice, Milan and Pavia, Italy; [2]Private Practice, Moscow, Russia; [3]Private Practice, Tel Aviv, Israel; [4]Private Practice, Treviso, Italy; [5]Private Practice, Barcelona, Spain; [6]Private Practice, Como and Lugano, Italy and Switzerland; [7]IBSA Institut Biochimique SA, Lugano, Switzerland; [8]Quantificare SA, Biot, France; [9]IBSA Farmaceutici Italia, Lodi, Italy

Abstract. *Background:* An increasing number of patients are seeking neck rejuvenation treatments, and different brands of HA fillers can be used to treat horizontal neck lines with favourable results. However, validated, standardized scales to grade the severity of horizontal neck wrinkles are lacking. Aim: to describe the development and validation of the 5-grade photographic IBSA Neck Lines Scale. *Methods:* 2 photographs were selected to create 5 morphed images of increasing visibility of the lines on the neck anatomical area. Fifty images of which half morphed and half real-life, were validated and assessed according to a 5-image scale by 5 experts who had previously undergone a specific training split into 2 rounds, 30 days apart, with the aim of evaluating inter- and intra-rater reliability. *Results:* Single-rater kappa scores ranging between 0.63 and 0.82, and a global kappa score of 0.75 were calculated as to intra-rater reliability, whereas when inter-rater agreement was assessed by an intra-class correlation coefficient, scores higher than 0.85 were observed. These results indicate excellent reliability. *Conclusions:* The IBSA Neck Lines Scale has proven to be a reliable and consistent assessment tool.

Key words: neck lines, photographic scale, aesthetic medicine, scale development, scale validation

Introduction

The neck is one of the most exposed anatomical areas and undergoes rather evident extrinsic and intrinsic early textural changes, therefore it is the target of several aesthetic rejuvenation procedures. While aging, many distinct imperfections inevitably appear, such as a wrinkled and sagging skin, dyschromic lesions, a blunting of the cervicomental angle, as well as unappealing Venus rings and platysmal bands[1]. In today's world, it is increasingly necessary to have a fresh and everlasting overall vibrant look; therefore, physicians have to be ready to distinguish any possible clinical scenario, in order to properly fulfill their patients' needs and carry out the best customized treatment. Several features characterize a bright and gentle-looking neck, such as a smooth skin with no pigmented or vascular lesions, the absence of any horizontal or vertical lines or any platysmal bands, a well-defined and firm jawline, and no visible protrusion of the sub-mandibular gland with normotrophic masseter muscles[2]. Several important structures which belong to the nervous, muscular and vascular systems of the entire craniofacial area cross the region of the neck. Anatomically speaking, the skin is the top layer, followed by the subcutaneous tissue, the superficial facial muscle plane, whereas the sub platysmal structures lie in the deeper layer (Figure 1). All these structures

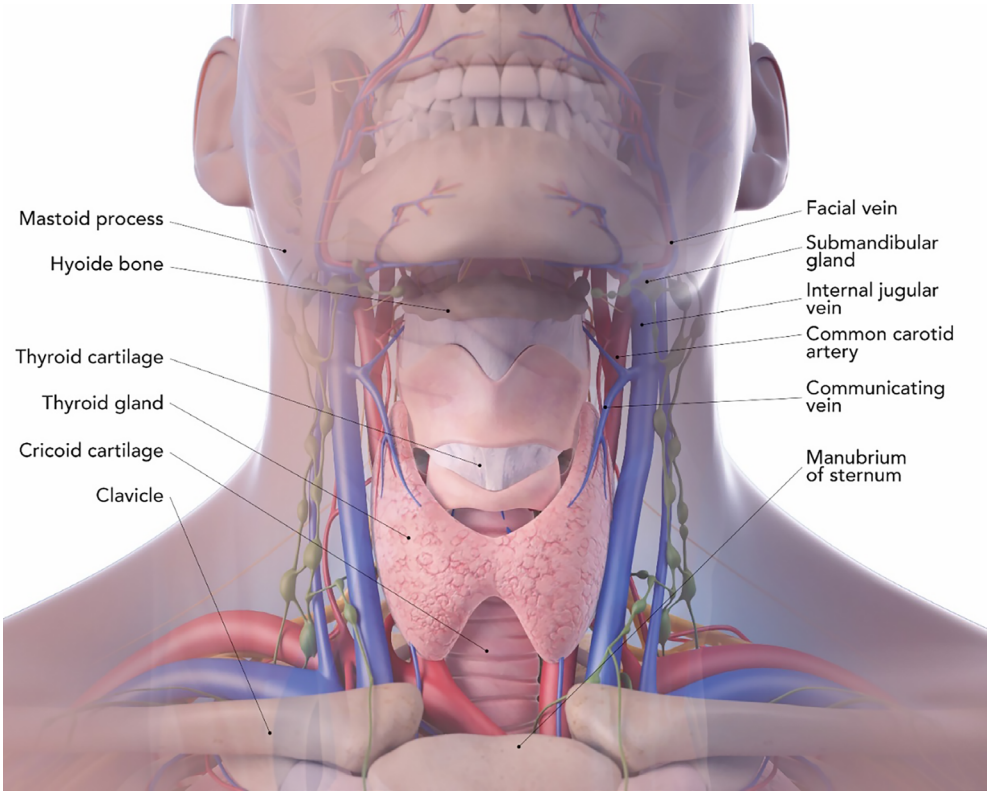

Figure 1. Neck anatomy.

are affected somehow by the ageing process[2]. The outer layer of the neck with its thin dermis and epidermis, undergoes multiple compressive and tensile stresses; furthermore, the number of anterior-posterior and lateral movements due to the contraction of the underlying platysma muscle may lead to the appearance of the so-called "necklace lines", with a linear horizontal pattern on the frontal side of the neck. Facial lines are first of all a direct result of a general process of skin aging, whereas neck lines with a horizontal pattern are common findings in younger individuals. It has been pointed out that daily movements to look at books, tablet, or even cell phones and postural patterns may cause wrinkles in the younger population; however, these lines are obviously made more evident by the overall aging of the skin[3]. Extrinsic events contribute to neck photoaging, which consists of collagen and elastin fiber degeneration, increased epidermal thickness, along with the appearance of elastotic collagen in the deeper layer[2,3]. Subcutaneous or the deeper adipose tissue is present in a variable amount in the epidermal-dermal layer. Wide strap-shaped skeletal muscles that form the cervical platysmal layer stretch until the mandibular edge of the clavicle bone. The cervical platysma is invested by the superficial layer of the deep cervical fascia, spanning upwards and creating the superficial-muscular aponeurotic system (SMAS). While aging, the retaining ligaments that bond the free medial edges anatomically close to the deep cervical fascia lose their strength, while the medial margins diminish and drop, causing the formation of platysma bands, which, together with muscle flaccidity and aging atrophy, can worsen and make more evident the cervical laxity, resulting in a neck that appears sagging, adynamic, and obtuse[4,2]. Due to the unstoppable loss of the intimate supporting structure of the mandible, the fat located in the jowl, which laid behind the surrounding soft tissues, is inevitably displayed. Ptosis of unsupported skin, together with the downward pull of platysma muscle, leads to the unpleasant "turkey

neck" deformity. Furthermore, contraction of the platysma muscle to give support to the floor of the oral cavity and the deeper areas of the neck, generates vertical fibrous bands, whereas the increasing loss of tone in the overlying anatomy makes horizontal rhytides appear. As decay due to aging progresses, the loss of blunting of the cervicomental angle is due to the descent of the hyoid bone and larynx[5]. Finally, deeper structures are affected, showing ptosis and hypertrophy, with the appearance of a visible bulge[4].

Neck rejuvenation approaches are diverse with different benefits and drawbacks: laser techniques, as well as ablative fractional radiofrequency procedures can improve dyschromia and photoaging, poor texture, and mild lines; injectable agents such as Botox can improve the appearance of the neck and jawline, and soften the occurring of neck banding secondary to muscle action; hyaluronic acid (HA) fillers are a well-known solution for treating horizontal neck lines, while defining the jawline and improving facial contours and balance; suction-assisted lipoplasty can address excessive preplatysmal fat when skin elasticity is fairly preserved; otherwise a neck lift represents a better option[6,7]. Invasive treatments pose several issues in terms of safety, as the anatomical region of the neck is both a pivotal passageway and the location of important vessels, nerves and glands; moreover, fibrosis and scars might easily appear after invasive procedures. The therapeutic choice varies greatly according to the patient's unique features. Despite its possible temporary and permanent complications, of which both the physician and the patient must be aware, surgery is rather often the option to go for when facing severe tissue deterioration and laxity. On the other hand, there are a number of intermediate stages in which the use of the filler could be the right answer to the patient's needs.

Currently, the assessment and selection of individual cases relies on the evaluation of medical doctors, and their experienced clinical eye and judgement. As a consequence, assessing what might be the best intervention to implement presents more than a challenge. In order to allow easier management, IBSA has designed a 5-grade photographic scale for neck lines, created by the physicians to facilitate their colleagues' practice. The intent is to help physicians overcome some clinical dilemmas by providing them with an objective, clear, and easy-to-use tool for a time-saving initial assessment in any clinical situation.

In compliance with current Italian regulations, this research did not undergo any ethics committee approval as it was conducted without the involvement of human beings. The present study followed the ethics of the Declaration of Helsinki. All data were treated following the procedures of the International Council for Harmonization of Technical Requirements for Pharmaceuticals for Human Use (ICH) Good Clinical Practice (GCP). At enrollment, all participants agreed to sign an informed consent form. The topic of this publication is the process that led to the development and validation of a photographic tool for aesthetic medicine purposes.

Methods

Scale development

Following a pattern implemented by previously published photonumeric assessment tools designed for other purposes, this scale was developed and made specific for the neck lines (Figure 2)[8-13]. A plastic surgery specialist, the responsible for research and development of QuantifiCare, and the scientific responsible for dermoaesthetics at IBSA carried out a selection from the database of a clinician searching for one image to represent a youthful neck and another one to be iconic for the most severe degree of lines, still suitable for being properly treated with a filler to depict some sort of clinical threshold, beyond which surgery is currently the only option available. A total of 50 photos of necks of patients between 40 and 79 years of age were chosen. Once this first selection was made, QuantifiCare and the 3 experts created a morphed photographic scale of 5 images corresponding to the increasing severity of lines on the neck (Figure 3). The images show the area from the lower margin of the mandible to the upper edge of the clavicle, while the chin is kept in resting position.

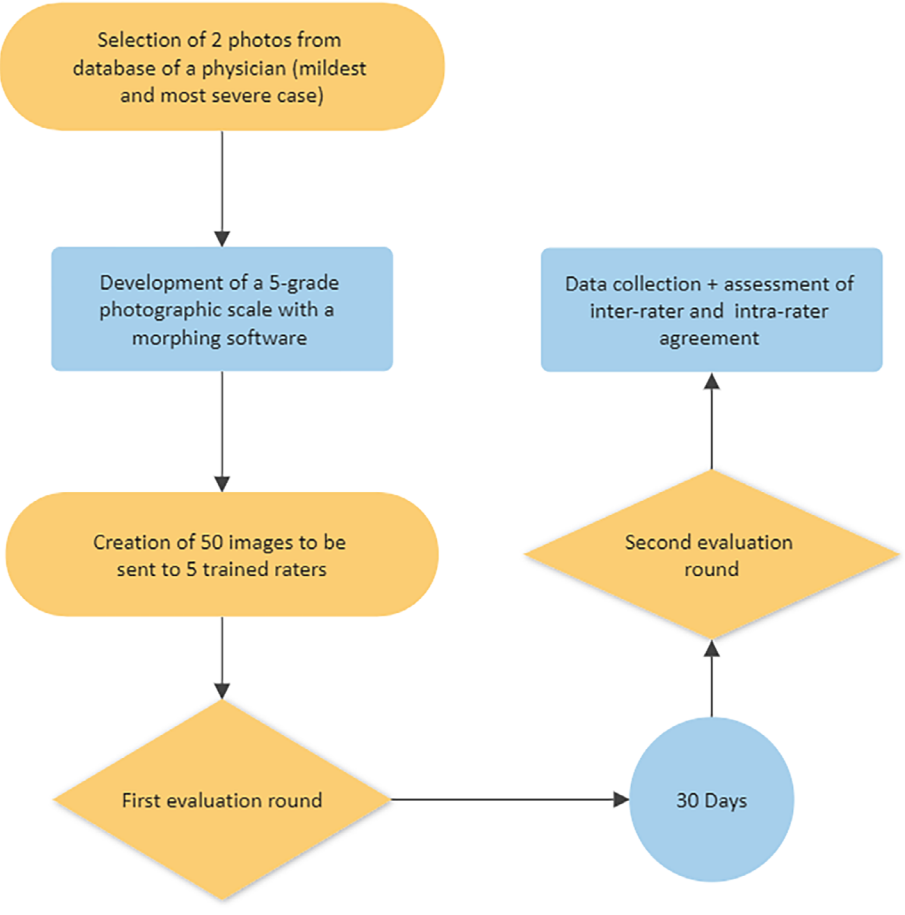

Figure 2. Algorithm of development and assessment of the IBSA Neck Lines Scale.

Considering the visibility and depth of the lines, 5 grades were identified with the following descriptors:

Grade 1: Smooth surface with superficial slightly visible lines of the neck;
Grade 2: Mildly deep and slightly visible lines of the neck;
Grade 3: Moderately deep and rather visible lines of the neck;
Grade 4: Moderately to severely deep and very visible lines of the neck;
Grade 5: Severely deep and extremely visible lines of the neck.

To execute an informed evaluation, a set of 50 photographs (i.e. 25 real and 25 morphed) was sent to 5 selected physicians. Before this stage, to perform a further assessment of the grades and their descriptors, the 5 morphed images were displayed to the raters in the form of a training session in which the 5 selected Grades and other non-selected morphed images were shown, and the validators' task was to match the descriptors accordingly. The exercise was performed twice with a week break and experts confirmed the previously developed scale.

Software characteristics

GAMP5 methodology, compliant to 21 CFR part 11 was used to develop and validate the software. Pseudonymized photographic data were organized into a Microsoft Access Database file first, and then as a Comma Separated Value file. Photographic data were acquired using a Phase one XF

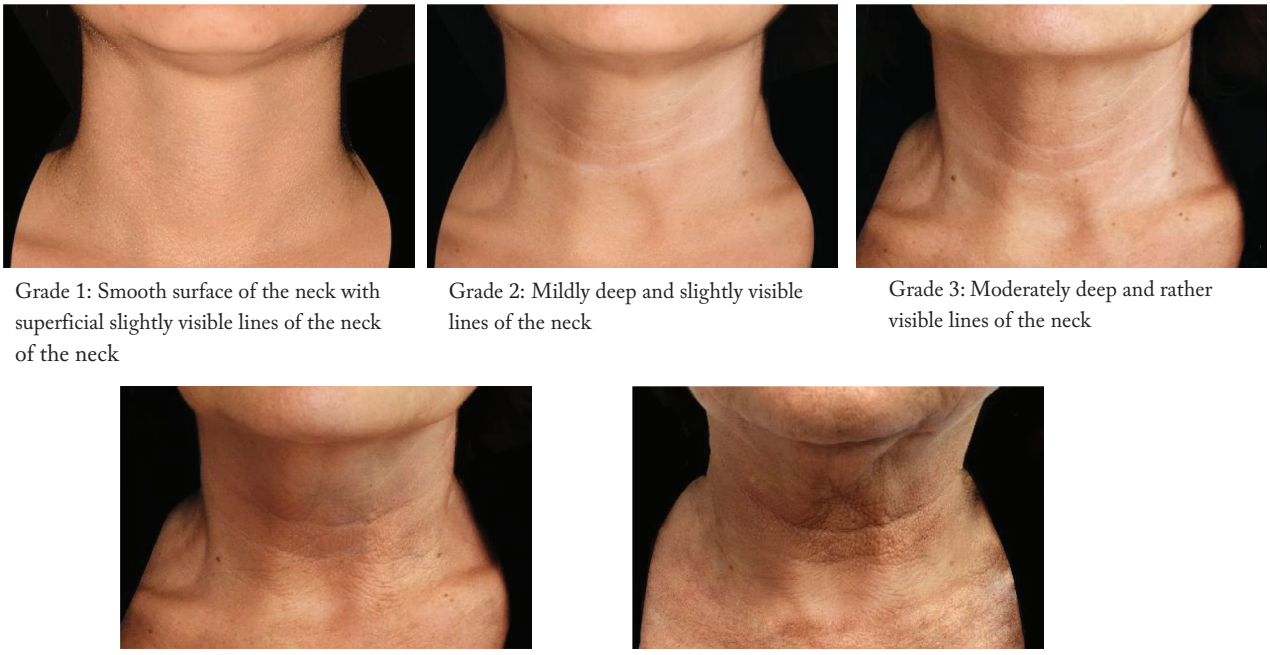

Grade 1: Smooth surface of the neck with superficial slightly visible lines of the neck of the neck

Grade 2: Mildly deep and slightly visible lines of the neck

Grade 3: Moderately deep and rather visible lines of the neck

Grade 4: Moderately to severely deep and very visible lines of the neck

Grade 5: Severely deep and extremely visible lines of the neck

Figure 3. The 5-grade IBSA Neck Lines Scale. Grade 1: Smooth surface with superficial slightly visible lines of the neck; Grade 2: Mildly deep and slightly visible lines of the neck; Grade 3: Moderately deep and rather visible lines of the neck; Grade 4: Moderately to severely deep and very visible lines of the neck; Grade 5: Severely deep and extremely visible lines of the neck.

IQ150 camera. Users had to be provided with Windows 10 and DirectX 9 or superior minimum of 2GB of free space on the hard drive, and 4GB of RAM memory along with a screen resolution of at least 1024x768. The software was split into pages with 1 photo for evaluation. Users could give a score to each page, before submitting and proceeding to the next one. Experts were invited to a Webex training session, to present a demo of the tool and get them familiar with the system, while sorting out any issues that could have slowed down the rating phase. Validators could restart and go through the training module at any time. A personal login for authentication was created for each single user. Of the five score options (Grade 1, Grade 2, Grade 3, Grade 4, and Grade 5) experts could only select one. The application displayed one photo per patient, in the center of the window, the image size was updated and the window automatically resized; it was possible to enlarge each photo; while full-screen visualization was available by clicking on it. Users could stop the procedure at any time and resume it when they desired. It was necessary to submit a score for each image before assessing the next one; yet, it was always possible to reassess any of the given scores. Scores were saved while navigating, and the procedure had no time limit. Scores were provided to IBSA in a CSV file, along with a report that contained results for each subject and evaluator's name.

Scale validation

The 50 photographs were sent to the 5 raters with a time-limit of 4 weeks for completion of each of two evaluation rounds, 4 weeks apart, to examine the same images in a different order. QuantifiCare was responsible for data collection and for sending them to IBSA for inter-rater evaluation (i.e. responses of the same rater on the same photo), and intra-rater evaluation (i.e. scores of the same photo among different raters) as described in detail in the following section.

Results

Intra-rater reliability (Table 1)

Scale validation involved calculating the intra-rater reliability between the first and second evaluations carried out by the same expert using weighted kappa scores with Fleiss-Cohen weights (the evaluation is a rate, while categories are ordinal). This analysis was performed by assessing each expert alone and considering all the first and the second available evaluations together. Kappa scores between 0.63 and 0.82 as to expert analysis, and a global kappa score of 0.75 when the 5 expert evaluations were analyzed all together were observed. Results indicate substantial or almost-perfect agreement between the first and the second evaluation on the same image (kappa scores range between 0 and 1; 0.61–0.80 indicate meaningful agreement; 0.81–1.00 indicate almost-ideal agreement).

Inter-rater reliability (Table 2)

An inter-rater agreement was measured by calculating the intra-class correlation coefficient (ICC [2,1] – to be used when all images are rated by the same raters who are a random subset of all possible raters) as described by Shrout and Fleiss. When first and second evaluations were analyzed separately and then together, findings indicated good or excellent reliability (i.e. intraclass correlation coefficient ranges between 0 and 1; values <0.5 indicate scarce reliability, values between 0.5 and 0.75 indicate moderate reliability, values between 0.75 and 0.9 indicate substantial reliability, and finally values greater than 0.90 indicate optimal reliability).

Table 1. Intra-rater reliability with Weighted Kappa Scores, calculated with Fleiss-Cohen Weights.

Experts	Weighted KAPPA	95% Lower Conf. Limit	95% Upper Conf. Limit
1	0.8238	0.7288	0.9189
2	0.7530	0.6544	0.8516
3	0.7963	0.6976	0.8951
4	0.7804	0.6902	0.8706
5	0.6371	0.5341	0.7401
TOTAL	0.7588	0.7138	0.8038

Table 2. Overall Inter-Rater reliability, as described by Shrout-Fleiss.

Evaluation 1	Evaluation 2
0.86592	0.86397
Total (Shrout-Fleiss Reliability - Random Set)	
0.91924	

Discussion and conclusions

The neck is particularly exposed to environmental damage being one of the very first anatomical regions to suffer premature aging dynamics; therefore, rejuvenation of this area has understandably become a desire for a growing audience worldwide. Being both anatomically and structurally a particularly delicate body area, the evaluation of any aesthetic defects in its skin and decay of related tissues is decisive in discriminating between an invasive surgical treatment with all its possible complications and a much less traumatic type of management. Moreover, patients are becoming increasingly demanding and well-informed as to aesthetic medicine, which makes it necessary for the physician to respond promptly to the most diverse requests. Hence, the need to provide aesthetic doctors with a reliable tool for an accurate assessment in their daily practice. This 5-image scale has shown to be a simple and immediate aid to promptly recognize diverse settings. The scale was validated by experienced doctors who confirmed its reliability. The tool here described identifies different stages of increasing severity of the visible lines on the neck surface that inevitably appear with ageing, each image with its descriptor is certainly affected by peculiar variables (e.g., gender, ethnic group, lifestyle, familiarity) which may potentially limit the use of this scale. However, such an iconographic and verbal classification tries to describe and simplify a possible real situation, while any other kind of evaluation relies on the physician's clinical intuition, skills, and experience. Therefore, understanding the benefits of this scale, its implementation, and customization in a real-life scenario is necessary.

In conclusion, the scale has shown to be consistent and reliable, as indicated by overall inter- and intra-rater data.

Funding: This project has been sponsored by IBSA Farmaceutici Italia.

Acknowledgments: The authors are grateful to Marta Castano, who helped with the writing of this manuscript.

Conflict of Interest: AL is employed at IBSA SA Switzerland; NL & ND are employed at Quantificare SA France; FG & GB are employed at IBSA Farmaceutici Italia. No other conflicts of interest are reported in this work.

References

1. Ellenbogen R, Karlin JV. Visual criteria for success in restoring the youthful neck. Plast Reconstr Surg. 1980; 66(6):826–837.
2. Mulhollad RS. Nonexcisional, minimally invasive rejuvenation of the neck. Clin Plast Surg. 2014; 41(1):11–31.
3. Tseng F, Yu H. Treatment of horizontal neck wrinkles with hyaluronic acid filler: a retrospective case series. Plast Reconstr Surg Glob Open. 2019; 7(8):e2366.
4. Mejia JD, Nahai FR, Nahai F, Momoh AO. Isolated management of the aging Neck. Semin Plast Surg. 2009; 23(4):264-73.
5. Coleman RS, Grover R. The anatomy of the aging face: volume loss and changes in 3-dimensional topography. Aesthet Surg J. 2006; 26(1S):S4–S9.
6. Carruthers A, Carruthers J. Cosmetic uses of botulinum exotoxin. Adv Dermatol. 1997; 12:325–347.
7. Manstein D, Herron GS, Sink RK, Tanner H, Anderson RR. Fractional photothermolysis: a new concept for cutaneous remodeling using microscopic patterns of thermal injury. Lasers Surg Med. 2004; 34(5):426–438.
8. Jones D, Donofrio L, Hardas B, et al. Development and validation of a photonumeric scale for evaluation of volume deficit of the hand. Dermatol Surg. 2016; 42(Suppl 1):S195-S202.
9. Sykes JM, Carruthers A, Hardas B, et al. Development and validation of a photonumeric scale for assessment of chin retrusion. Dermatol Surg. 2016; 42(Suppl 1):S211-S218.
10. Donofrio L, Carruthers A, Hardas B, et al. Development and validation of a photonumeric scale for evaluation of facial skin texture. Dermatol Surg. 2016; 42(Suppl 1):S219-S226.
11. Jones D, Carruthers A, Hardas B, et al. Development and validation of a photonumeric scale for evaluation of transverse neck lines. Dermatol Surg. 2016; 42(Suppl 1):S235-S2424.
12. Cassuto D, Pellacani G, Tateo A, et al. Development and Validation of IBSA Photographic Scale for the Assessment of Inner Upper Arm Laxity. Clin Cosmet Investig Dermatol. 2021; 14:1465-1471.
13. Tateo A, Siquier-Dameto G, Artzi O, et al. Development and Validation of IBSA Photographic Scale for the Assessment of Neck Laxity. Clin Cosmet Investig Dermatol. 2021; 14:349-354.

Correspondence:
Received: 13 December 2022
Accepted: 13 October 2023
Gilberto Bellia, PharmD
IBSA Farmaceutici Italia, Lodi (LO), Italy
E-mail: gilberto.bellia@ibsa.it